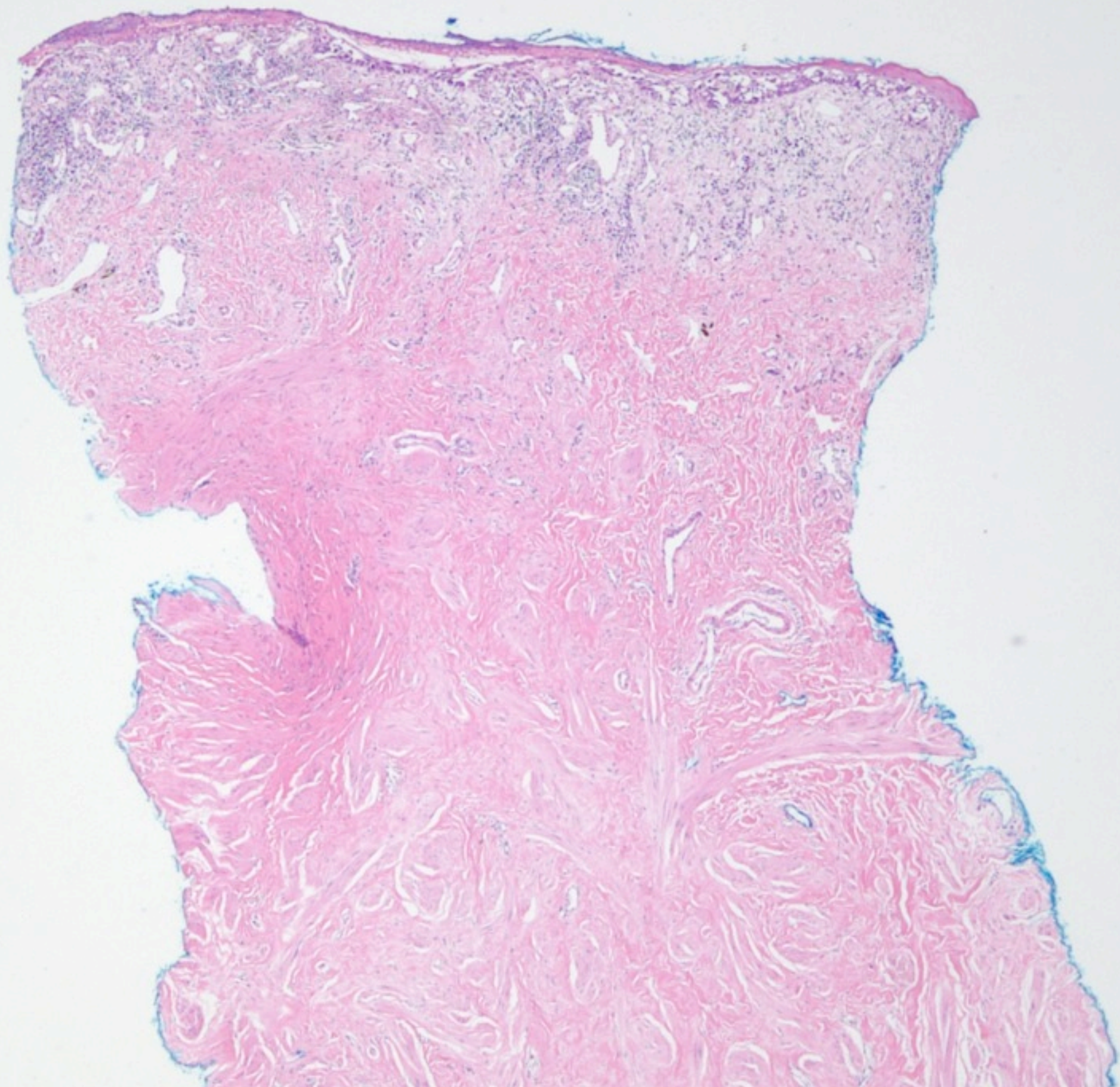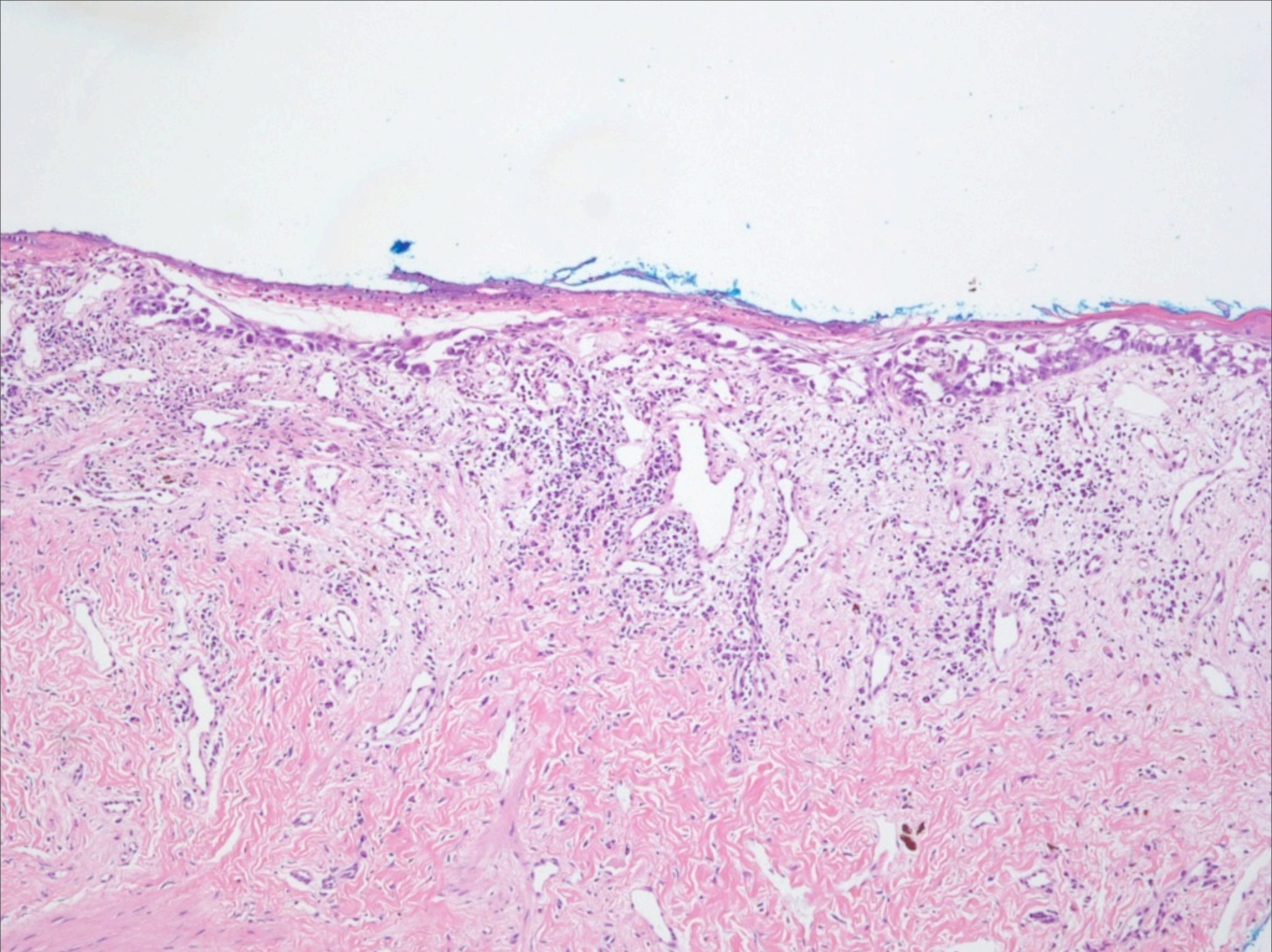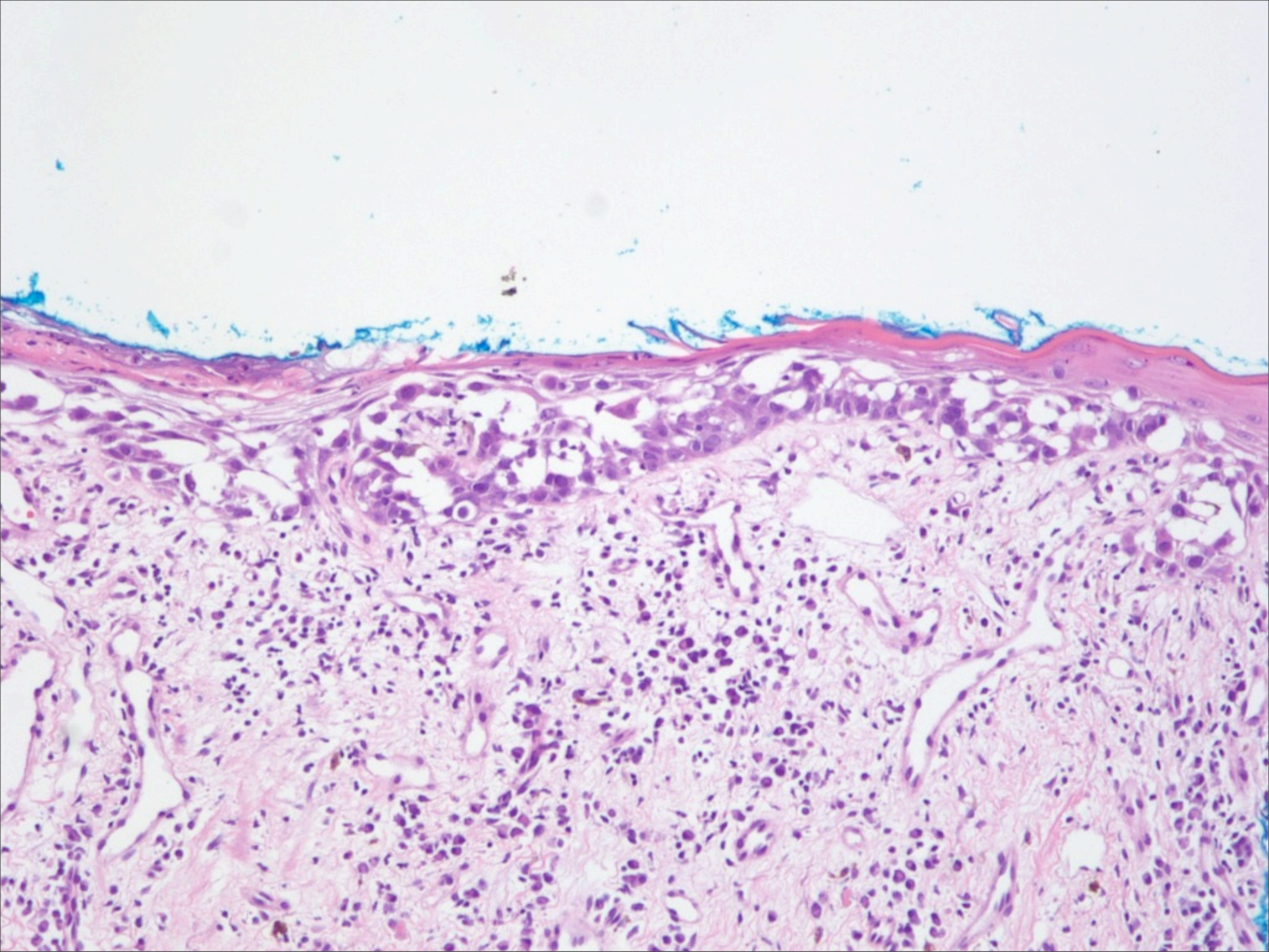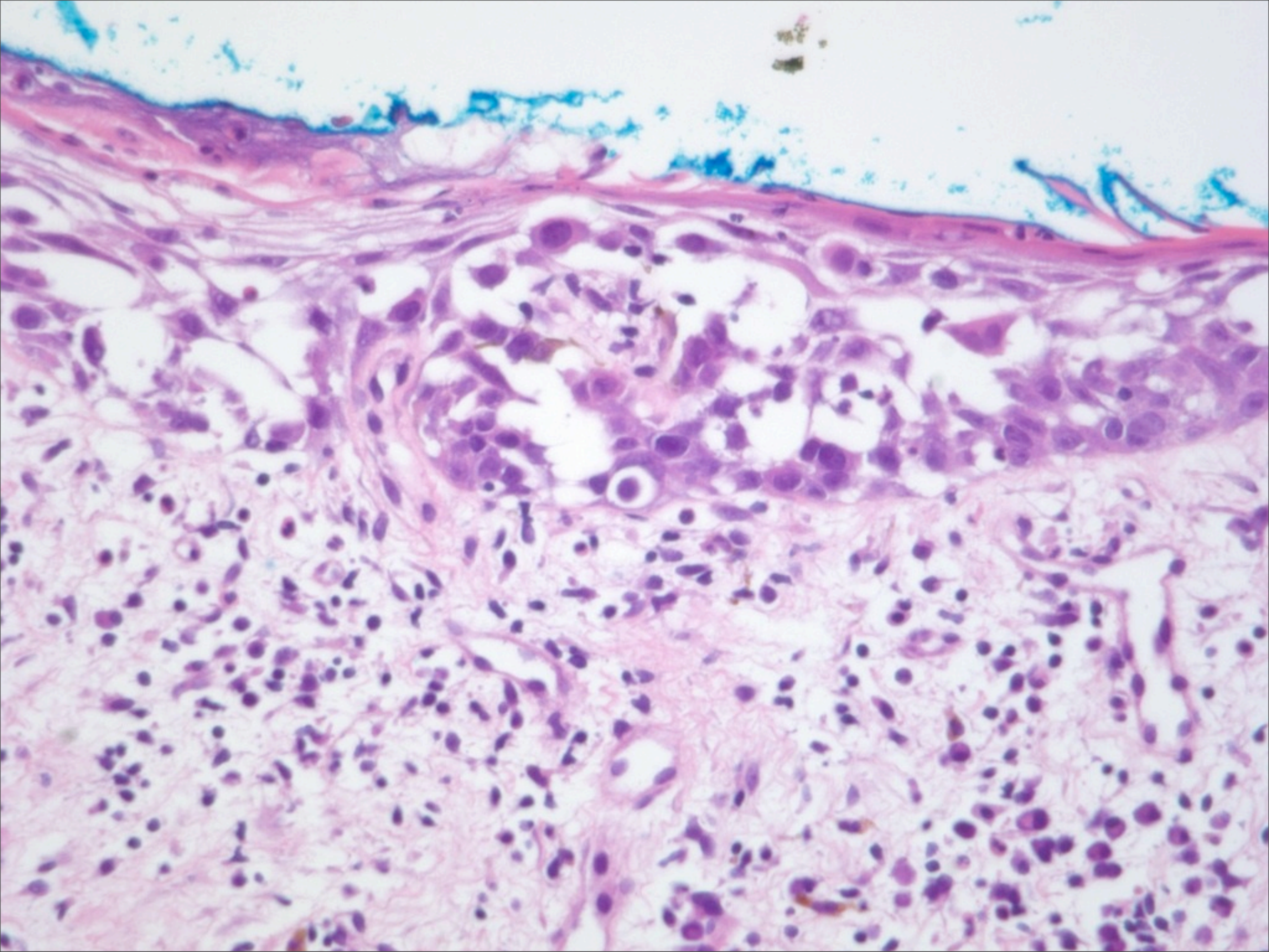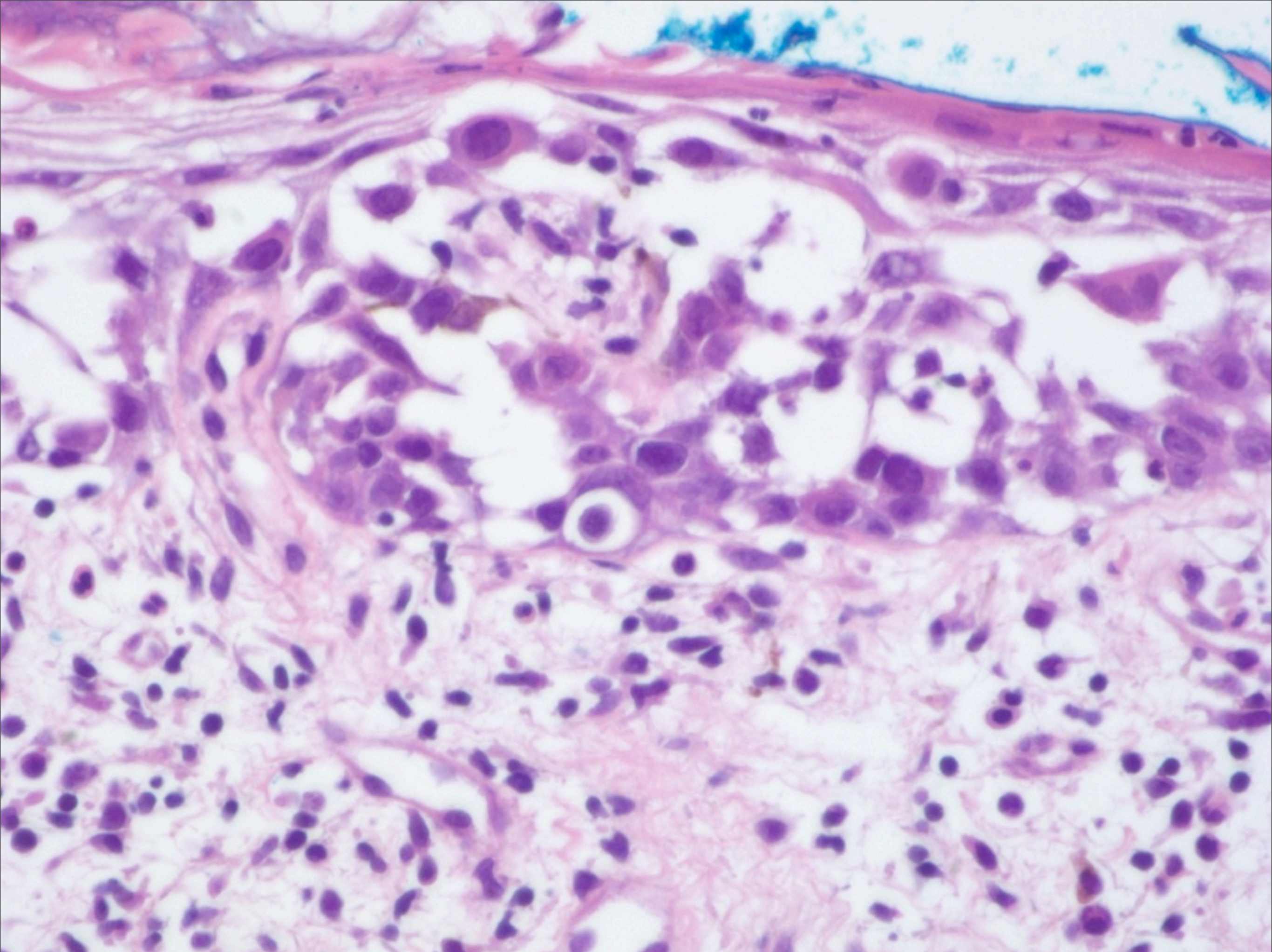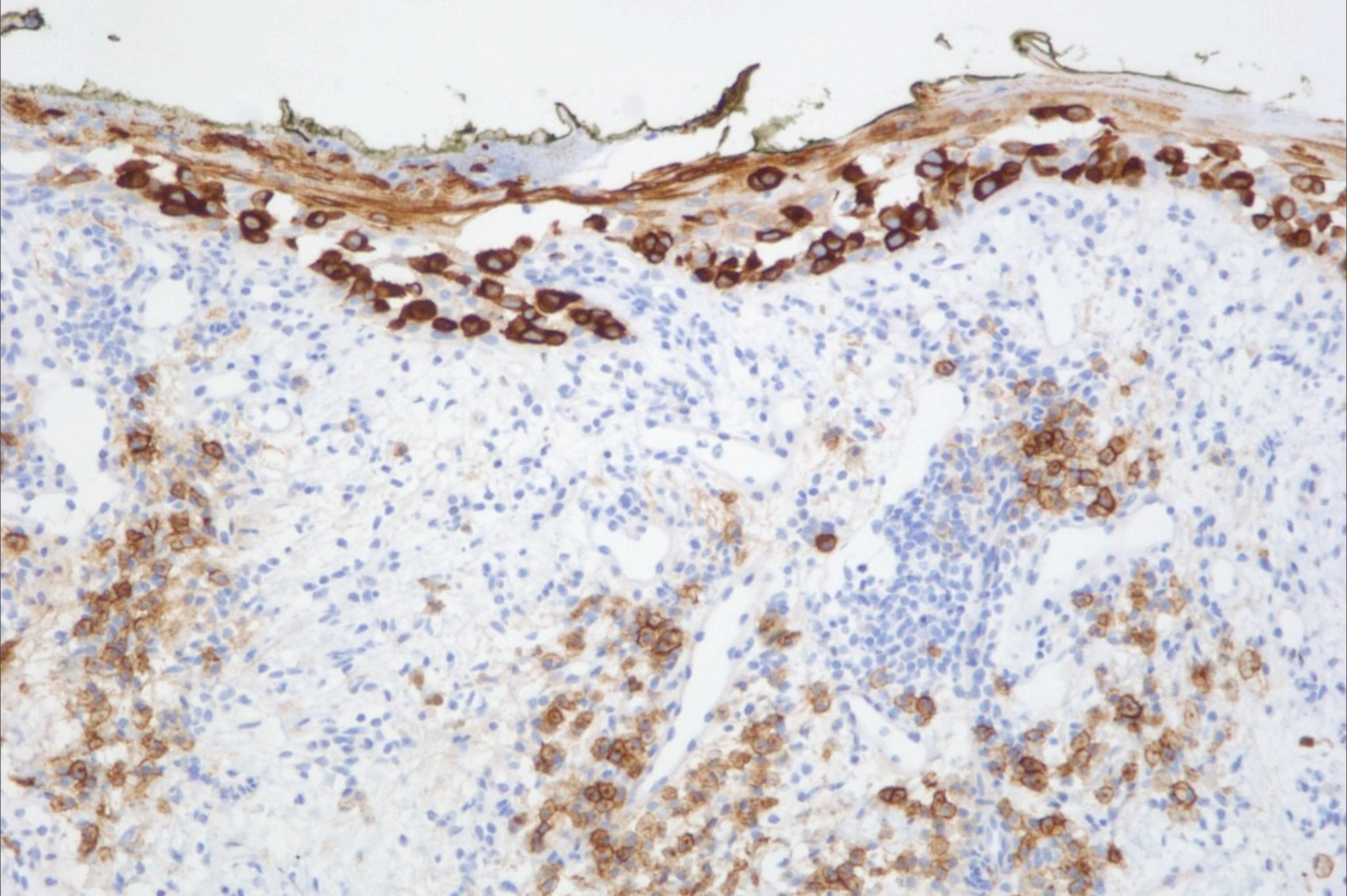




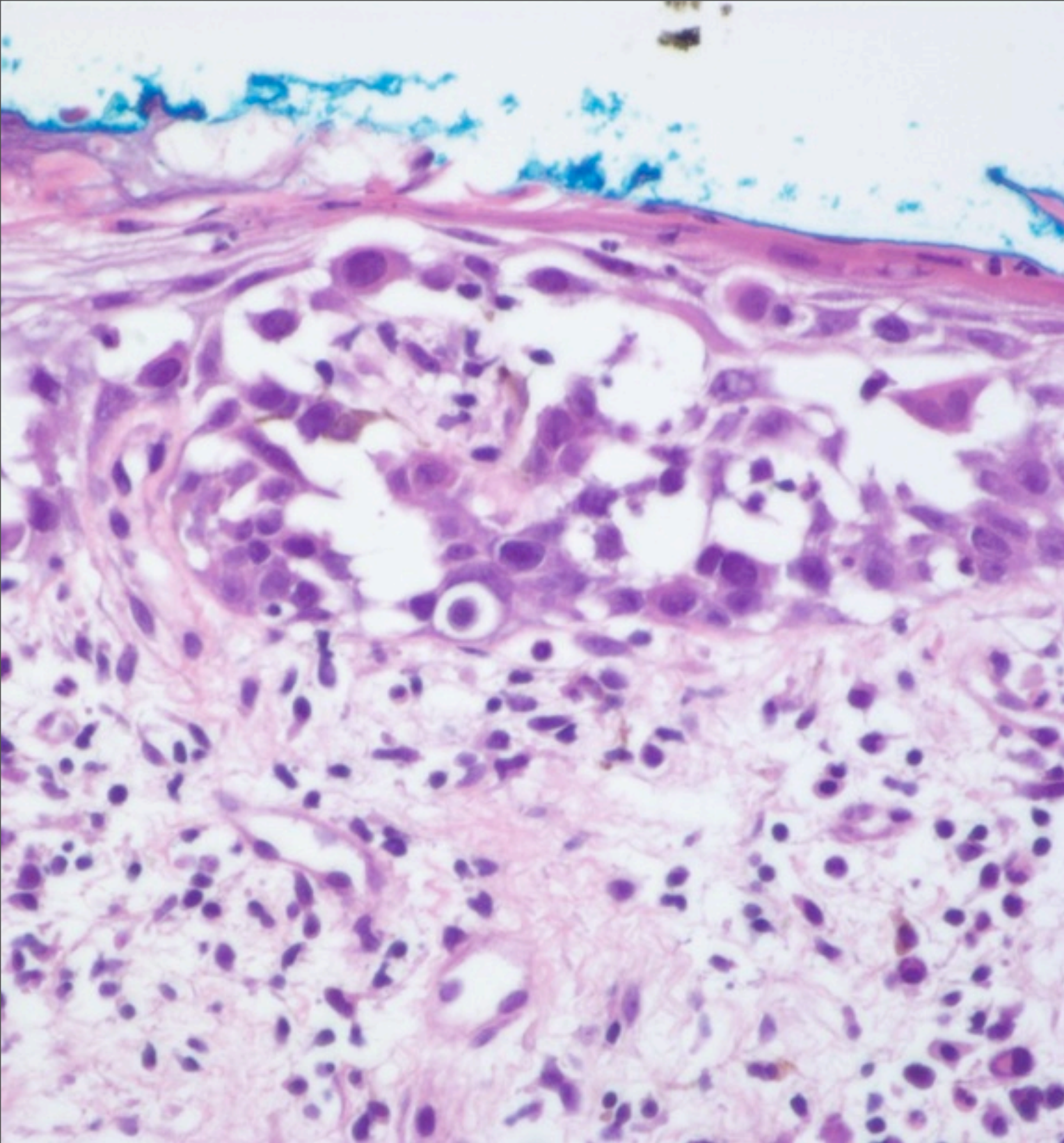
EMA





# Paget's Disease of the Nipple





Confirm with  
immunostains

Rule out underlying  
breast carcinoma

Intraepidermal Collections of Malignant Cells  
Cells show different morphology than adjacent  
keratinocytes